



## An Important Cause of Hip Pain in a Patient with Rheumatoid Arthritis: Femoral Fragility Fracture

*Romatoid Artritli Hastada Kalça Ağrısının Önemli Bir Sebebi: Femur Frajilite Kırığı*

**Derya Karacıf**

Hitit University Çorum Erol Olçok Training and Research Hospital, Department of Physical Medicine and Rehabilitation, Çorum, Türkiye

### Abstract

Rheumatoid arthritis (RA) is the most common chronic systemic inflammatory disease. In RA, systemic inflammation, autoantibodies, glucocorticoid use, and physical inactivity can lead to the development of osteoporosis. The prevalence of osteoporosis in RA is approximately twice that of the healthy population. The most significant clinical outcome of osteoporosis is fragility fractures. Fragility fractures in patients with RA impair quality of life and functional status and may result in increased mortality. This patient population should be assessed in terms of bone mineral density and fracture risk, and appropriate treatments should be planned when necessary to prevent fragility fractures. If a fragility fracture occurs, diagnosis and treatment should not be delayed. In this case report, we discuss a patient with RA who was diagnosed with a femoral fragility fracture. The aim is to raise awareness of osteoporosis and fragility fractures in RA.

**Keywords:** Rheumatoid arthritis, osteoporosis, fracture

### Öz

Romatoid artrit (RA); en sık görülen, kronik, sistemik, enflamatuvar hastalıktır. RA'da sistemik enflamasyon, otoantikorlar, glukokortikoid kullanımı, fiziksel inaktivite nedeniyle osteoporoz gelişebilir. RA'da osteoporoz prevalansı sağlıklı popülasyonun yaklaşık iki katıdır. Osteoporozun en önemli klinik sonucu frajilite kırığıdır. RA'lı hastalarda frajilite kırığı; yaşam kalitesini, fonksiyonel durumu kötüleştirir, mortaliteye sebep olabilir. Bu hasta grubu, kemik mineral yoğunluğu ve kırık riski açısından değerlendirilmeli, frajilite kırığını önlemek için gerekli durumlarda uygun tedaviler planlanmalıdır. Frajilite kırığı oluştu ise tanı ve tedavisinde geç kalınmamalıdır. Bu olgu sunumunda femurda frajilite kırığı tespit ettiğimiz RA'lı bir hasta tartışılmıştır. RA'da osteoporoz ve frajilite kırığı konusunda farkındalığın artırılması amaçlanmıştır.

**Anahtar kelimeler:** Romatoid artrit, osteoporoz, fraktür

### Introduction

Rheumatoid arthritis (RA) is a chronic inflammatory disease characterized by arthritis of peripheral joints. One of the most significant complications of RA is bone loss resulting from increased bone resorption and decreased bone formation. Bone loss may lead to periarticular osteopenia, joint erosions, and osteoporosis (1).

Osteoporosis is a common systemic disease characterized by low bone mass and microarchitectural deterioration of bone tissue (2). The prevalence of osteoporosis in RA is approximately twice that of the healthy population. Despite this, osteoporosis

is often underdiagnosed and inadequately treated in the RA population (3).

The most significant clinical consequence of osteoporosis is fragility fractures (2). Defined as fractures occurring spontaneously or due to minimal trauma, fragility fractures in RA negatively impact quality of life and functional status and may lead to mortality (1).

In this paper, we aim to present a case of RA in which a fragility fracture of the femur was identified and discuss the effects of RA on bone metabolism, as well as the diagnosis and treatment methods for osteoporosis.

**Corresponding Author/Sorumlu Yazar:** Derya Karacıf MD, Hitit University Çorum Erol Olçok Training and Research Hospital, Department of Physical Medicine and Rehabilitation, Çorum, Türkiye

**E-mail:** derya24160@hotmail.com **ORCID ID:** orcid.org/0000-0002-5877-6480

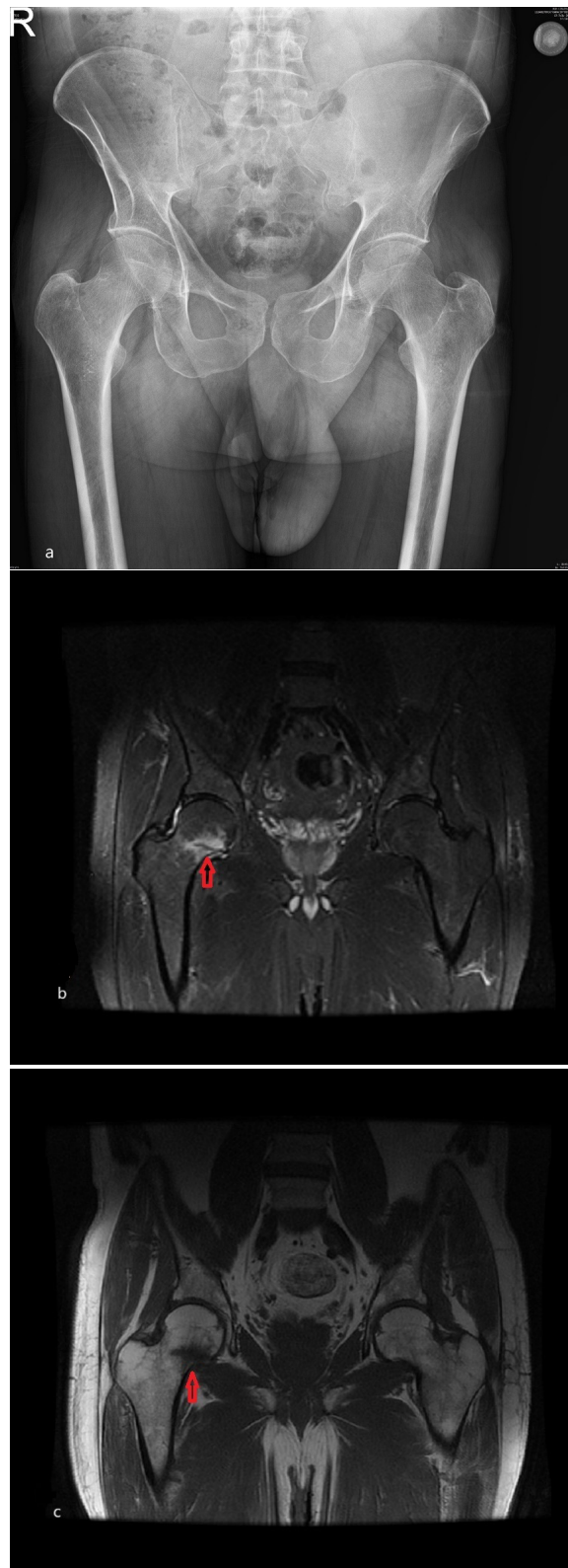
**Received/Geliş Tarihi:** 23.05.2025 **Accepted/Kabul Tarihi:** 10.06.2025 **Epub:** 14.08.2025 **Publication Date/Yayınlanma Tarihi:** 24.03.2026

**Cite this article as/Atf:** Karacıf D. An important cause of hip pain in a patient with rheumatoid arthritis: femoral fragility fracture. Turk J Osteoporos. 2026;32(1):71-4



## Case Report

A 51-year-old male patient presented to our outpatient clinic with complaints of right hip pain. He reported difficulty walking due to the pain. The pain had started approximately one month earlier and worsened with movement but decreased slightly with rest. There was no nocturnal pain. There was no recent history of trauma. The patient had been under follow-up for RA for about ten years and was taking methotrexate 15 mg/week and prednisolone 5 mg/week. On physical examination, range of motion (ROM) of the right hip joint was complete, although pain was noted particularly with external rotation and abduction. Flexion abduction external rotation and flexion, adduction, and internal rotation tests were positive on the right. Lumbar ROM was normal. Femoral stretch, sacroiliac joint stress, and sciatic stretch tests were negative. Neurological examination was normal. Biochemical tests revealed the following: leukocyte count: 17.83 ( $n=4-10 \times 10^9/L$ ), erythrocyte sedimentation rate: 71 ( $n=0-20$  mm/h), C-reactive protein: 53.29 ( $n=0-5$  mg/L), rheumatoid factor (RF): 217.9 ( $n=0-20$  mmol/L), calcium (Ca): 8.8 ( $n=8.8-10.6$  mg/dL), phosphorus: 3.36 ( $n=2.3-4.7$  mg/dL), 25-hydroxyvitamin D<sub>3</sub> [25-(OH)D<sub>3</sub>]: 33.1 ( $n=30-100$  ng/mL), parathyroid hormone (PTH): 70 ( $n=12-72$  pg/mL), alkaline phosphatase: 68 ( $n=30-120$  u/L), thyroid-stimulating hormone: 0.38 ( $n=0.35-4.2$  mIU/L), glomerular filtration rate: 97, creatinine: 0.9. Disease activity was assessed using the disease activity score-28 (DAS-28): 4.8. Anteroposterior pelvic and lumbosacral two-view X-rays revealed no pathology (Figure 1a). Magnetic resonance imaging of the right hip revealed hypointense signals on T1-weighted images and hyperintense signals on T2-weighted images in a 3 cm area at the femoral head-neck junction, consistent with edematous changes. A linear hypointense line on T2-weighted images was observed, suggestive of a microfracture (Figures 1b and 1c). Given these findings, the patient was evaluated for fragility fracture, and bone mineral density was measured by dual-energy X-ray absorptiometry. T-score values were: L1-L4: -1.8, femoral neck: -2.0. Fracture risk assessment tool (FRAX) score revealed a 10-year major osteoporotic fracture risk of 5.9% and a hip fracture risk of 0.5%. Due to the history of steroid use, the patient was started on alendronate 70 mg once weekly and a Ca-vitamin D<sub>3</sub> supplement (1200 mg Ca/day and 880 IU vitamin D<sub>3</sub>/day). In addition, 2 g of sulfasalazine in divided daily doses was added to the RA treatment to suppress disease activity in the patient with high acute phase reactants and high disease activity. The patient was referred to the orthopedic and traumatology department, where surgery was not recommended. Consequently, the patient was advised to use a cane for 3 weeks, to perform partial weight-bearing on the affected extremity, and to do isometric strengthening exercises for the hip muscles. For pain control, diclofenac sodium 150 mg/day was prescribed. At the 3-week follow-up, the patient reported a pain score of 1 on the visual analogue scale. A home exercise program was provided including balance and coordination training, strengthening exercises for bilateral lower extremities, and gait training.



**Figure 1.** a) No pathology detected in the anteroposterior pelvic radiograph, b) T2-weighted MRI showing hyperintense signal alteration at the femoral head-neck junction with a linear hypointense line suggestive of microfracture, c) T1-weighted MRI demonstrating hypointense signal changes in the same region

MRI: Magnetic resonance imaging

## Discussion

RA is the prototype of osteoimmunological diseases characterized by bone loss. RA and osteoporosis share common risk factors such as female sex. Traditional osteoporosis risk factors like advanced age, low body mass index, menopause, diabetes, and thyroid disease are also relevant in RA patients. In addition, RA-specific risk factors include systemic inflammation associated with disease activity, autoantibodies, glucocorticoid use, disease duration, altered body composition, and physical inactivity (2). Inflammatory cytokines that play a central role in RA pathogenesis also influence the development of osteoporosis in the general population (4). Cytokines such as interleukin (IL)-1, IL-6, and tumor necrosis factor- $\alpha$  stimulate osteoclasts directly and inhibit osteoblast function, promoting bone resorption (5). Moreover, inflammation leads to loss of muscle mass and function, which reduces mechanical loading on bones, further diminishing bone mass and increasing fragility and fall risk (4).

Glucocorticoids, widely used in RA treatment, increase bone resorption, reduce bone formation, and alter bone quality through osteocyte apoptosis, resulting in decreased bone mineral density. They also contribute to muscle mass and function loss, thereby promoting bone loss, falls, and fractures (4). Inflammation and glucocorticoids may suppress gonadotropin-releasing hormone, leading to reduced sex hormone production and subsequent hypogonadism. However, glucocorticoids may also reduce inflammation, joint pain, and stiffness in RA, which may mitigate some of their harmful effects on bone mineral density. The optimal glucocorticoid dose that balances effective RA management and minimal harm to bone density remains unclear (3).

Given that high-dose methotrexate is known to cause bone loss in oncology patients, its impact on bone mineral density (BMD) has become a topic of interest in the treatment of RA, where it is frequently used. In a study conducted by Rexhepi et al. (6) in premenopausal RA patients, no negative effect of methotrexate on BMD was found.

Osteoporosis and fractures in patients with RA are more common in individuals with disease duration exceeding 10 years, RF positivity, high titer anti-citrullinated protein antibodies, high disease activity, and cumulative structural damage (2). Tong et al. (7) also found that osteoporosis and vertebral fractures in RA patients were associated with long disease duration and high disease severity. In our case, high acute phase reactants and a high DAS-28 score indicate that inflammation has not been sufficiently suppressed. Given the known effects of disease activity and inflammation on osteoporosis and fractures, the patient's RA treatment has been reviewed. The patient was informed about his current condition and conventional synthetic disease-modifying antirheumatic drugs combination therapy was deemed appropriate. 2 g of sulfasalazine was added to the current treatment to suppress disease activity. After suppressing disease activity, prednisolone was planned to be discontinued.

The 2022 guideline of the National Osteoporosis Foundation recommends BMD screening for all RA patients over the age of 50 (8). Similarly, the 2022 guideline of the American College of Rheumatology on glucocorticoid-induced osteoporosis recommends BMD screening for all patients aged 40 years and older who have been taking  $\geq 2.5$  mg/day of prednisone (or its equivalent) for 3 months or longer (9).

To assess fracture risk, the use of the FRAX tool is recommended. However, FRAX does not take into account RA-specific factors such as disease severity, duration, or autoantibody positivity. Thus, it may not accurately predict fracture risk in this patient population (4). RA patients may experience fractures even at higher BMD levels compared to individuals without RA (2). A meta-analysis identified vertebrae, hips, forearms, and proximal humerus as the most common sites of fragility fractures in RA patients (10). Recently, an increased incidence of hip fractures in this population has been reported (4). In our case as well, a microfracture was identified in the femoral neck region.

There is currently no specific guideline for the prevention and treatment of osteoporosis in RA. Existing guidelines recommend initiating pharmacological treatment in postmenopausal women and men over 50 years of age with RA if the T-score is  $\leq -2.5$ , or if the T-score is between -1.0 and -2.5 and the FRAX score indicates a  $\geq 20\%$  risk for major osteoporotic fracture or  $\geq 3\%$  risk for hip fracture (8,9). The American College of Rheumatology's 2022 guideline on glucocorticoid-induced osteoporosis stratifies patients into risk categories. Patients with a history of osteoporotic fracture, as in our case, are categorized as very high risk. For patients over 40 years of age in this category, oral bisphosphonate therapy is strongly recommended over no treatment; PTH or PTH-related protein therapy is conditionally recommended over antiresorptives; and denosumab, intravenous bisphosphonates, raloxifene, and romosozumab are conditionally recommended over no treatment (9).

Osteoporosis is the most significant etiological factor in femoral neck fractures. These fractures are most often managed surgically, with options including internal fixation or arthroplasty. The choice of surgical approach depends on factors such as the patient's age, general health, pre-fracture mobility level, degree of fracture displacement, and time elapsed since the fracture. In non-displaced fractures, conservative treatment may be considered (11). In our case, conservative management was recommended due to the presence of a microfracture.

## Conclusion

One of the most significant complications of RA is the development of osteoporosis. Fragility fractures, which may result from osteoporosis, are important causes of morbidity and mortality in these patients. Therefore, RA patients should be evaluated for osteoporosis and treated appropriately when necessary. In patients presenting with pain complaints, the possibility of fragility fracture should be considered. Early

diagnosis and appropriate treatment of such fractures can help improve quality of life and prevent disability.

### Ethics

**Informed Consent:** A written informed consent was obtained from the patient.

### Footnotes

**Financial Disclosure:** The author declared that this study received no financial support.

### References

1. Ajeganova S, Andersson M, Forslind K, Gjerdtsson I, Nyhäll-Wählin BM, Svensson B, et al. Long-term fracture risk in rheumatoid arthritis: impact of early sustained DAS28-remission and restored function, progressive erosive disease, body mass index, autoantibody positivity and glucocorticoids. A cohort study over 10 years. *BMC Rheumatol.* 2023;7:23.
2. Llorente I, García-Castañeda N, Valero C, González-Álvarez I, Castañeda S. Osteoporosis in rheumatoid arthritis: dangerous liaisons. *Front Med (Lausanne).* 2020;7:601618.
3. Baker R, Narla R, Baker JF, Wysham KD. Risk factors for osteoporosis and fractures in rheumatoid arthritis. *Best Pract Res Clin Rheumatol.* 2022;36:101773.
4. Wysham KD, Baker JF, Shoback DM. Osteoporosis and fractures in rheumatoid arthritis. *Curr Opin Rheumatol.* 2021;33:270-6.
5. Xue AL, Wu SY, Jiang L, Feng AM, Guo HF, Zhao P. Bone fracture risk in patients with rheumatoid arthritis. *Medicine.* 2017;96:e6983.
6. Rexhepi S, Rexhepi M, Sahatçiu-Meka V, Mahmutaj V, Boshnjaku S. The impact of low-dose disease-modifying anti-rheumatics drugs (DMARDs) on bone mineral density of premenopausal women in early rheumatoid arthritis. *Med Arch.* 2016;70:101-3.
7. Tong JJ, Xu SQ, Zong HX, Pan MJ, Teng YZ, Xu JH. Prevalence and risk factors associated with vertebral osteoporotic fractures in patients with rheumatoid arthritis. *Clin Rheumatol.* 2020;39:357-64. Erratum in: *Clin Rheumatol.* 2020;39:2023.
8. LeBoff MS, Greenspan SL, Insogna KL, Lewiecki EM, Saag KG, Singer AJ, et al. The clinician's guide to prevention and treatment of osteoporosis. *Osteoporos Int.* 2022;33:2049-102. Erratum in: *Osteoporos Int.* 2022;33:2243.
9. Humphrey MB, Russell L, Danila MI, Fink HA, Guyatt G, Cannon M, et al. 2022 American College of Rheumatology Guideline for the prevention and treatment of glucocorticoid-induced osteoporosis. *Arthritis Rheumatol.* 2023;75:2088-102.
10. Jin S, Hsieh E, Peng L, Yu C, Wang Y, Wu C, et al. Incidence of fractures among patients with rheumatoid arthritis: a systematic review and meta-analysis. *Osteoporos Int.* 2018;29:1263-75.
11. Keklikçi K, Çilli F, Pehlivan Ö, Kuşkucu M. Femur boyun kırıkları. *TOTBİD (Türk Ortopedi ve Travmatoloji Birliği Derneği) Dergisi.* 2009;8:1-6.