



The Clinical Significance of Ultrasound Guided Needling the Peroneal Muscles for Chronic Ankle Instability and Lateral Leg Pain

Kronik Ayak Bileği İnstabilitesi ve Lateral Bacak Ağrısında Peroneal Kasların Ultrason Eşliğinde İğneleme Tedavisinin Klinik Önemi

Demet Ferahman¹, Bülent Alyanak², Burak Tayyip Dede³, Mustafa Hüseyin Temel⁴, Mustafa Turgut Yıldızgören⁵, Fatih Bağcıer¹

¹University of Health Sciences Türkiye, Başakşehir Çam and Sakura City Hospital, Department of Physical Medicine and Rehabilitation, İstanbul, Türkiye

²Gölcük Necati Çelik State Hospital, Clinic of Physical Medicine and Rehabilitation, Kocaeli, Türkiye

³University of Health Sciences Türkiye, Prof. Dr. Cemil Taşcıoğlu City Hospital, Department of Physical Medicine and Rehabilitation, İstanbul, Türkiye

⁴University of Health Sciences Türkiye, Sultan 2. Abdülhamid Han Training and Research Hospital, Department of Physical Medicine and Rehabilitation, İstanbul, Türkiye

⁵Konya City Hospital, Clinic of Physical Medicine and Rehabilitation, Konya, Türkiye

Keywords: Peroneal muscle dysfunction, myofascial trigger points, ultrasound-guided dry needling, chronic ankle instability, lateral leg pain
Anahtar kelimeler: Peroneal kas disfonksiyonu, miyofasiyal tetik noktalar, ultrason eşliğinde kuru iğneleme, kronik ayak bileği instabilitesi, lateral bacak ağrısı

Dear Editor,

The peroneal muscles, including the peroneus longus (PL) and peroneus brevis (PB), are critical components of the lower leg's lateral compartment (1). Muscles that originate on the fibula and insert on the base of the first metatarsal and medial cuneiform (PL) and the tuberosity of the fifth metatarsal (PB); these muscles are primarily ankle evertors and stabilizers (1-3). They play a crucial role in dynamic postural control, providing a counterforce against excessive supination and preventing lateral ankle sprains (2,3). Muscle dysfunction in these tissues is often linked to chronic lateral ligament instability, entrapment, recurrent sprains, and neuromuscular deficiencies, resulting in persistent gait and balance impairments.

Myofascial trigger points (MTrPs) in the peroneal muscles may mimic lateral ankle pain and instability, typically described as referred pain along the lateral aspect of the leg and foot (Figure 1) (4,5). When active, trigger points in these muscles cause muscle pain, weakness, and proprioceptive changes, creating a cycle of vulnerability to repeat ankle injuries. The PB, notably, can also refer pain to the lateral malleolus and dorsum of the foot, complicating differential diagnoses. Since the functional anatomy of these muscles

suggests that identification and treatment of MTrPs should be a central component in the restoration of ankle stability and normal biomechanics in those with chronic ankle instability (3-5).

Diagnosis of peroneal muscle MTrPs has proven to be difficult clinically, especially because the PB is located underneath the PL. Interrater reliability in finding taut bands, nodules, and local twitch responses (LTRs) has been variable as palpation techniques could not detect these reliably with a good degree of accuracy (5). Moreover, recent studies have shown, simply examining the structures is not very precise, especially for deeper structures, again demonstrating the need for something more objective for diagnosis. The potential for misdiagnosis and the difficulty differentiating between peroneal dysfunction and other lateral ankle pathologies suggests that imaging-based assessment should be included in clinical practice.

Musculoskeletal ultrasound improves the precision of both trigger point detection and intervention, but there are limitations. Lower resolution limits detection of subtle fascial and muscular pathologies, especially at deeper anatomical levels, and it is operator dependent. Musculoskeletal ultrasound, however, substantially enhances the treatment of peroneal muscle

Corresponding Author/Sorumlu Yazar: Demet Ferahman MD, University of Health Sciences Türkiye, Başakşehir Çam and Sakura City Hospital, Department of Physical Medicine and Rehabilitation, İstanbul, Türkiye

E-mail: demetferahman@gmail.com **ORCID ID:** orcid.org/0000-0002-0803-3814

Received/Geliş Tarihi: 17.03.2025 **Accepted/Kabul Tarihi:** 10.04.2025 **Epub:** 05.08.2025 **Publication Date/Yayınlanma Tarihi:** 24.03.2026

Cite this article as/Atf: Ferahman D, Alyanak B, Dede BT, Temel MH, Yıldızgören MT, Bağcıer F. The clinical significance of ultrasound guided needling the peroneal muscles for chronic ankle instability and lateral leg pain. Turk J Osteoporos. 2026;32(1):80-1



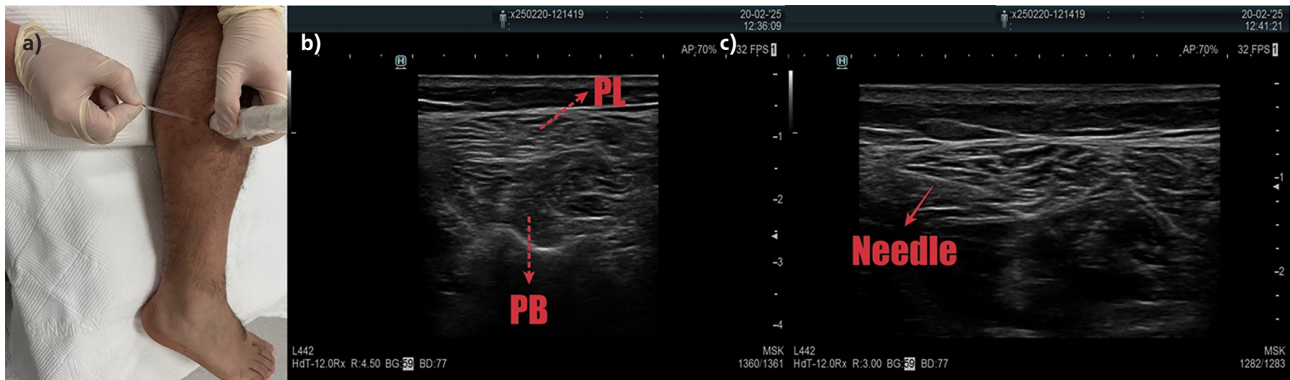


Figure 1. a) Patient positioned in a side-lying position with the treated leg on top, allowing optimal access to the peroneal muscles, b) Ultrasound image of the peroneal muscle anatomy. The peroneus longus (PL) is located more superficially, while the peroneus brevis (PB) is positioned deeper. Real-time visualization aids in identifying myofascial trigger points and fascial restrictions, c) Needle placement under ultrasound guidance. The needle is directed precisely into the (PL) muscle, allowing for accurate targeting of myofascial trigger points while minimizing the risk of injury to adjacent structures

dysfunction through the real-time identification of anatomy, morphology, fascial compromise and MTrPs. Although manual palpation is the first step, ultrasound identifies the situated taut bands and fibrotic changes in the trigger point with precision and is used to guide the needles in dry needling treatments. In conclusion, ultrasound-guided dry needling greatly enhances treatment accuracy, allows for easier LTR activation, and minimizes the risk of neurovascular damage. Due to the diagnostic and therapeutic difficulty of peroneal myofascial dysfunction, ultrasound-guided technique should be introduced in routine clinical practice to improve patient outcomes.

Footnotes

Authorship Contributions

Concept: B.A., B.T.D., M.H.T., M.T.Y., Design: B.A., M.H.T., F.B., Data Collection or Processing: D.F., B.T.D., Analysis or Interpretation: D.F., B.T.D., M.H.T., F.B., Literature Search: D.F., M.T.Y., F.B., Writing: D.F., F.B.

Conflict of Interest: No conflict of interest was declared by the authors.

Financial Disclosure: The authors declared that this study received no financial support.

References

1. Hertel J. Functional instability following lateral ankle sprain. *Sports Med.* 2000;29:361-71.
2. Mansur H, Durigan JLQ, Contessoto S, Maranhão DA, Nogueira-Barbosa MH. Evaluation of the healing status of lateral ankle ligaments 6 weeks after an acute ankle sprain. *J Foot Ankle Surg.* 2024;63:637-45.
3. Salom-Moreno J, Ayuso-Casado B, Tamaral-Costa B, Sánchez-Milá Z, Fernández-de-Las-Peñas C, Albuquerque-Sendín F. Trigger point dry needling and proprioceptive exercises for the management of chronic ankle instability: a randomized clinical trial. *Evid Based Complement Alternat Med.* 2015;2015:790209.
4. Dede BT, Alyanak B, Temel MH, Yıldızgören MT, Bağcıer F. Reply to: evaluation of the healing status of lateral ankle ligaments six weeks after an acute ankle sprain. *J Foot Ankle Surg.* 2025;64:213-4.
5. Sanz DR, Lobo CC, López DL, Morales CR, Marín CS, Corbalán IS. Interrater reliability in the clinical evaluation of myofascial trigger points in three ankle muscles. *J Manipulative Physiol Ther.* 2016;39:623-34.